



**Dr Michael Wertheim,**  
**Consultant Ophthalmologist.**  
**Tel 9312 6033.**

# Recognising acute glaucoma

Acute angle closure glaucoma (AACG) is an ophthalmic emergency that, if not recognised and treated appropriately and promptly, is potentially blinding.

## Aqueous dynamics.

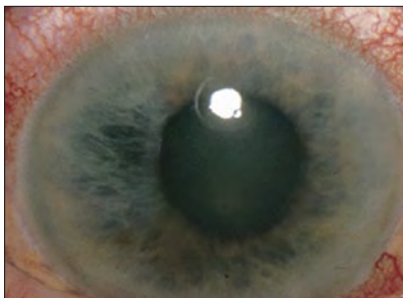
Aqueous drains out through the trabecular meshwork, which is at the iridocorneal angle of the anterior chamber (AC); any blockage of this angle will lead to a decrease in drainage and therefore an increase in pressure in the eye. Any cause of a decrease in AC depth will put the eye at a higher risk of AACG. The most common causes of this abnormal anatomy are long-sightedness (a shorter eye and therefore a shallower AC) and cataract (swelling of the lens causes a shallower AC). When the iris dilates in the shallow anterior chamber, it bunches up at the iridocorneal angle and obstructs the flow of aqueous out of the eye.

## Those at risk.

Patients at the highest risk of AACG are female, long-sighted, over age 60 and have no previous history of glaucoma. AC depth can be determined by using a simple pen torch (see Figure 1). This test can determine whether a patient has a shallow anterior chamber and therefore is at risk of developing AACG. The test is especially helpful in patients who present with a vague history of “seeing halos,” headache and nausea (i.e. possible pre-AACG symptoms). The test may also be beneficial when considering starting patients on anticholinergics, sympathomimetics and antidepressants, as these drugs cause pupil dilation and therefore put any patients who have an associated shallow AC at risk of AACG.

## Presentation.

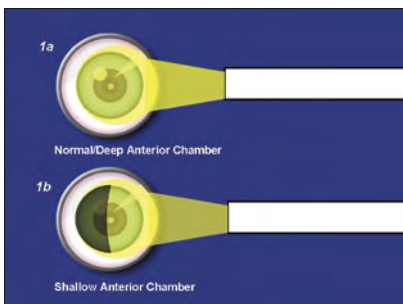
Patients present with deep pain around the eye, redness, watering and very poor vision. Systemically, they feel nauseas and often vomit due to the raised intraocular pressure (IOP) that sometimes reaches 80mmHg (normal 10-22mmHg). With extremely high IOP, the central retinal vein is at risk of occluding. Examination reveals a red eye, hazy cornea and a mid-dilated and non-reactive pupil (Figure 2).




■ *Fig 2: Classic signs of acute angle closure glaucoma (AACG): red eye with a hazy cornea and mid-dilated pupil.*

## Treatment.

On suspicion of AACG, patients should be referred immediately to an ophthalmologist. Treatment includes lowering of IOP by means of intravenous and oral acetazolamide and topical IOP lowering medications such as prostaglandins, beta blockers and pilocarpine to constrict the pupils. Surgical treatment includes an immediate YAG laser iridotomy. Iridotomies are performed on both eyes as the unaffected eye is at high-risk of developing AACG. If the AACG episode is associated with an enlarging cataractous lens then cataract extraction is performed as soon as it is safe. ■



■ *Fig 1: The pen torch is shone over the cornea and iris from the temporal side. In a normal or deep anterior chamber the light is seen to illuminate the whole iris (1a). When the AC is shallow then the nasal iris is in shadow (1b).*



# Eye Surgery Foundation

*The Way Forward for  
 Day Surgery is Clear*

- Perth’s only freestanding Ophthalmic Day Hospital
- Improving ophthalmic research and technology for the Western Australian community for 18 years.
- Recent recertification ISO 9001 standard

**Dr Ian Anderson**  
 Tel: 6380 1855

**Dr Malcolm Burvill**  
 Tel: 9275 2522

**Dr Ian Chan**  
 Tel: 9388 1828

**Dr Steve Colley**  
 Tel: 9385 6665

**Dr Dru Daniels**  
 Tel: 9381 3409

**Dr Blasco D’Souza**  
 Tel: 9258 5999

**Dr Graham Furness**  
 Tel: 9440 4033

**Dr Richard Gardner**  
 Tel: 9382 9421

**Dr Annette Gebauer**  
 Tel: 9389 6666

**Dr David Greer**  
 Tel: 9481 1916

**Dr Boon Ham**  
 Tel: 9474 1411

**Dr Philip House**  
 Tel: 9316 2156

**Dr Jane Khan**  
 Tel: 9385 6665

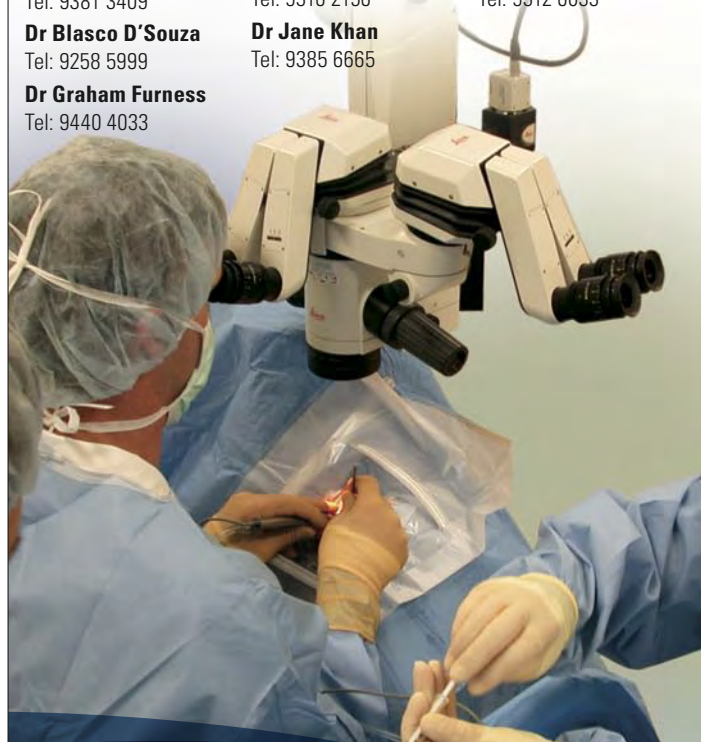**Dr Ross Littlewood**  
 Tel: 9374 0620

**Dr Nigel Morlet**  
 Tel: 9385 6665

**Dr Stuart Ross**  
 Tel: 9250 7702

**Dr Andrew Stewart**  
 Tel: 9381 5955

**Dr Michael Wertheim**  
 Tel: 9312 6033



## Expert day surgery for

- Cataract Extraction and Lens Implant
- Pterygium • Glaucoma • Oculoplastic Surgery
- Strabismus • Corneal Transplant
- All types of Refractive Surgery – LASIK, LASEK, PRK, CTK, Phakic Lens and Refractive Lens Exchange (RLE)

**Contact:** Matthew Whitfield Ph: 9481 6277

Email: [info@eyesurgeryfoundation.com.au](mailto:info@eyesurgeryfoundation.com.au)

42 Ord Street West Perth WA 6005