

# Idiopathic intracranial hypertension and the eye



By Dr Stephen Colley,  
Ophthalmologist

Idiopathic intracranial hypertension (IIH) – syn. Pseudotumour Cerebri or Benign Intracranial Hypertension – presents with symptoms of a malignant headache and visual disturbance, making immediate neuroimaging mandatory.

## Demographics

The typical patient is a female in early adulthood who is overweight or who has a history of recent weight gain. IIH incidence is 1 in 100,000 in the general population, increasing up to 20 per 100,000 in obese women.

IIH has also been found, though less frequently, in men and women of all body types and ages. In cases of IIH in children under ten, obesity and gender are not significant factors.

## Diagnosis

Diagnosis in patients with suggestive symptoms (headache, nausea, vomiting, tinnitus and visual disturbance) and a normal neurological examination (except for papilloedema and sixth nerve palsies), is confirmed once a CT or MRI has ruled out a space occupying lesion. A cerebrospinal fluid opening pressure >20cm of water is diagnostic.

## Cause

This is unknown. A likely possibility is reduced CSF absorption due to dysfunction of the arachnoid villi or elevated cerebral venous pressure.

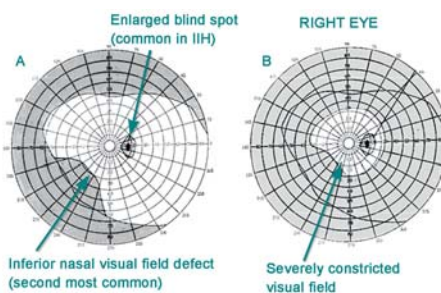
Intracranial hypertension may be secondary to other things. These include specific drugs (tetracyclines, Vitamin A analogues, lithium),

growth hormone treatments, dural venous sinus thrombosis and other underlying systemic diseases (like meningitis, uremia, or lupus).

## Visual effects

Transient visual obscurations (TVOs) are the characteristic visual symptom of IIH. These consist of brief episodes of visual loss (grey-outs lasting a few seconds) that are often precipitated by changes in position. Blurred vision, visual field loss and diplopia may also occur.

It is important to appreciate that IIH can result in profound vision loss. The severity of visual symptoms often dictate the management of this condition. Serial visual field examination is important in monitoring IIH.



■ Figure: Progressive (A to B) visual field loss in idiopathic intracranial hypertension.

## Management

Medical management to reduce CSF pressure includes weight loss (improvement may occur with only modest weight reduction) and acetazolamide (Diamox; typically 250mg QID, up to 3g per day). Serial lumbar punctures are frequently used to monitor progress and may also lower the CSF pressure long term. Most patients do well with medical management.

Surgery should be considered for patients with persistent symptoms despite medical management. Early surgical intervention is the treatment of choice if progressive vision loss is present. Surgical options include optic nerve sheath fenestration (ONSF), lumbo-peritoneal and ventriculo-peritoneal shunting.

Other indications for surgery include severe visual loss at presentation, poor compliance with treatment or inability to perform accurate visual field tests.

The effectiveness of ONSF should make it the primary treatment for visual loss.

Lumbo-peritoneal shunting is usually reserved for patients in whom headache is the major problem or in whom vision loss progresses despite ONSF.

This clinical update is made possible through support of the Eye Surgery Foundation



# Eye Surgery Foundation

- Perth's only freestanding Ophthalmic Day Hospital
- Improving ophthalmic research and technology for the Western Australian community for 15 yrs.
- Awarded Australian Council on Healthcare Standards (ACHS) accreditation for four years.

## Expert day surgery for

- Strabismus • All types of Refractive Surgery – LASIK, LASEK, PRK, CTK, Phakic Lens and Refractive Lens Exchange (RLE)
- Cataract Extraction and Lens Implant • Pterygium • Corneal Transplant • Oculoplastic Surgery • Glaucoma

**Dr Ian Anderson**  
Tel: 9385 3917

**Dr David Greer**  
Tel: 9481 1916

**Dr Ross Littlewood**  
Tel: 9374 0620

**Dr Rob Paul**  
Tel: 9339 8740

**Dr Bill Ward**  
Tel: 9535 1300

**Dr Steve Colley**  
Tel: 9385 6665

**Dr Boon Ham**  
Tel: 9474 1411

**Dr Ed Mele**  
Tel: 9430 6775

**Dr Stuart Ross**  
Tel: 9250 7702

**Dr Blasco D'Souza**  
Tel: 9258 5999

**Dr Philip House**  
Tel: 9316 2156

**Dr Nigel Morlet**  
Tel: 9385 6665

**Dr Andrew Stewart**  
Tel: 9381 5955

**Dr Graham Furness**  
Tel: 9440 4033

**Dr Chris Kennedy**  
Tel: 9382 9422

**Dr Alan Nicoll**  
Tel: 9381 6311

**Dr Anita Tandon**  
Tel: 9440 4033

