



# Ocular toxoplasmosis

By Dr Michael Wertheim, Ophthalmologist. Tel 9312 6033

Ocular toxoplasmosis should be considered in all patients who present with posterior ocular symptoms, especially immunocompromised patients. The *Toxoplasma gondii* (*T. gondii*) parasite has a complex lifecycle; the cat is the definitive host and intermediate hosts include pigs and sheep; humans most commonly contract the disease by ingesting uncooked meat containing tissue cysts.

Vertical transmission occurs when a pregnant woman contracts a primary infection and passes it on transplacentally. Congenital disease tends to be more severe if acquired in the first trimester but transmission rates are highest in the third trimester. Congenital disease manifests in many ways, from spontaneous abortion to asymptomatic infants that present later in life with ocular scarring or reactivation.

## Making the diagnosis

Symptoms may be non-specific and include the onset of new floaters, flashing lights, decreased visual acuity, ocular pain and redness. Ophthalmic examination is often all that is needed to make the diagnosis.

The appearance of unilateral active retinal toxoplasmosis is classic (Figure 1). Re-activated lesions have a pigmented area (old scar) associated with an adjacent fluffy white lesion (active lesion). There is usually a single lesion evident.

In immunocompromised patients, ocular signs are non-specific and may be confused with other retinal inflammation or infection; multiple lesions may be bilateral and may or

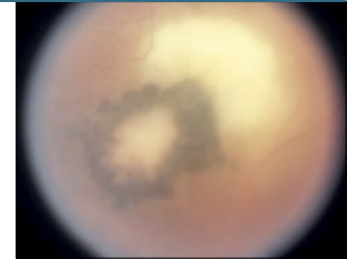
may not be associated with a pigmented scar (Figure 2).

Recognising atypical forms of the disease can be challenging yet definitive diagnosis is essential before starting treatment. The best way to make the diagnosis is by isolating *T. gondii* PCR from ocular fluid; by an anterior chamber tap or a vitreous biopsy. Blood levels of *T. gondii* IgM antibodies may help; levels rise during acute acquired toxoplasmosis and typically remain positive for less than a year. (IgG antibodies remain positive for life but are non-specific because a high proportion of the population has a positive IgG for non-ocular infections).

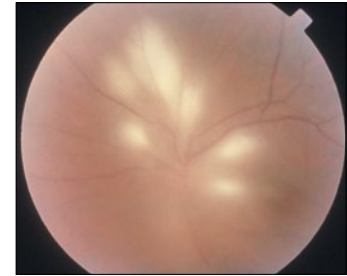
## Treatment

This is determined mainly by the immune status of the patient and location of the lesion in the retina. All immunocompromised patients need treatment.

In immunocompetent patients, the disease is usually self-limiting and, if not sight-threatening, can be closely monitored in clinic. However, all sight-threatening lesions need treatment; lesions within the temporal arcades,



■ Fig 1.



■ Fig 2.

near the optic nerve, and perhaps associated with an extensive vitritis or very decreased vision.

A 2002 survey of 78 American Uveitis Society specialists revealed 24 different regimens using 9 different parasitic drugs. Only 17% used an oral corticosteroid when treating all cases of ocular toxoplasmosis in immunocompetent patients while others used corticosteroid only for specific indications. So agreement on the ideal treatment is debatable and contentious. The most common drugs used are a combination of pyramethamine, sulphadiazine, clindamycin and prednisolone. Currently, an effective treatment is a course of azithromycin alone, with or without prednisolone.

*This clinical update is supported by the Eye Surgery Foundation*